



<http://dx.doi.org/10.5935/1981-2965.20140007>  
<http://www.higieneanimal.ufc.br>

*A Review*

***Clinostomum complanatum* (Trematoda, Digenea): a parasite of birds and fishes with zoonotic potential in southern Brazil. A Review**

*Clinostomum complanatum* (Trematoda, Digenea): um parasita de aves e peixes com potencial zoonótico no sul do Brasil. Uma Revisão

**Fernando Jonas Suttili<sup>1</sup>, Luciane Tourem Gressler<sup>1</sup>, Luis Fernando Vilani de Pelegrini**

<sup>2\*</sup>

---

**ABSTRACT:** *Clinostomum complanatum* is a digenean trematoda belonging to the Clinostomidae family with a complex life cycle, usually taking molluscs and fishes as intermediate hosts and birds as final hosts. Man may become the final host by eating raw or undercooked fish meat carrying the metacercarial stage of the parasite. Therefore, this trematode deserves great attention not only for the losses in production and discards of fish carcasses, but also for its zoonotic potential. Parasitic diseases transmitted to man through fish consumption have been especially reported in Eastern countries, where the habit of eating dishes based on raw fish meat is common. Nonetheless, *C. complanatum* has been reported in free-living fishes and specimens in fish farms in southern Brazil, thus representing a risk to the health of fish consumers. Strict regulations should be implemented in Brazil in order to control the quality of the fish destined for human consumption, and public awareness of the dangers of eating raw fish should be raised.

**Key words:** Fish parasite, public health, digenean, metacercariae, raw meat

**Resumo:** *Clinostomum complanatum* é um trematoda digenético pertencente à família Clinostomidae com um ciclo de vida complexo, tendo normalmente moluscos e peixes como hospedeiros intermediários e aves como hospedeiros finais. O homem pode tornar-se o

hospedeiro final através do consumo de carne de peixe crua ou mal cozida portando as metacercárias. Assim, este parasita merece atenção não só pelas perdas na produção e no descarte de carcaças de peixes que acarreta, mas também pelo seu potencial zoonótico. Parasitoses transmitidas através do consumo de peixes têm sido relatadas especialmente em países do oriente, onde o hábito de consumir pratos que utilizam carne de peixe crua é comum. Entretanto, a presença de *C. complanatum* em peixes de vida livre e de criações já foi reportada no sul do Brasil, o que representa um risco à saúde dos consumidores de carne de peixe. Regulamentações efetivas devem ser implementadas no Brasil a fim controlar a qualidade do peixe destinado ao consumo humano e os riscos da ingestão de carne de peixe crua devem ser amplamente esclarecidos perante a comunidade.

**Palavras-chave:** Parasita de peixe, saúde pública, digenético, metacercária, carne crua

---

\*Author for correspondence: E-mail: \* pelegri@smail.ufsm.br

Recebido em 20.12.2013. Aceito em 28.3.2014

<sup>1</sup> Programa de Pós Graduação em Farmacologia, Departamento de Fisiologia e Farmacologia, Universidade Federal de Santa Maria, 97105-900, Santa Maria, RS, Brazil

<sup>2</sup> Departamento de Medicina Veterinária Preventiva, Universidade Federal de Santa Maria, 97105-900, Santa Maria, RS, Brazil

## Introduction

Public health issues caused by parasitic diseases transmitted through the consumption of raw or insufficiently cooked fish meat has called the attention of researchers and authorities in the recent years. The increasing concern about the importance of food quality to people's

health, such as the idea of not baking food too much to preserve its nutrients, may prompt the acquisition of parasites (OKUMURA et al., 1999). In Brazil there is a great demand for dishes prepared with raw fish, like sushi and sashimi, due to the wide acceptance of oriental cuisine. Other influences such as the Peruvian with the

ceviche, the Spanish with the marinated and the Dutch with the green herring also constitute a risk to consumer's health for they similarly make use of raw fish meat (BARROS et al., 2006).

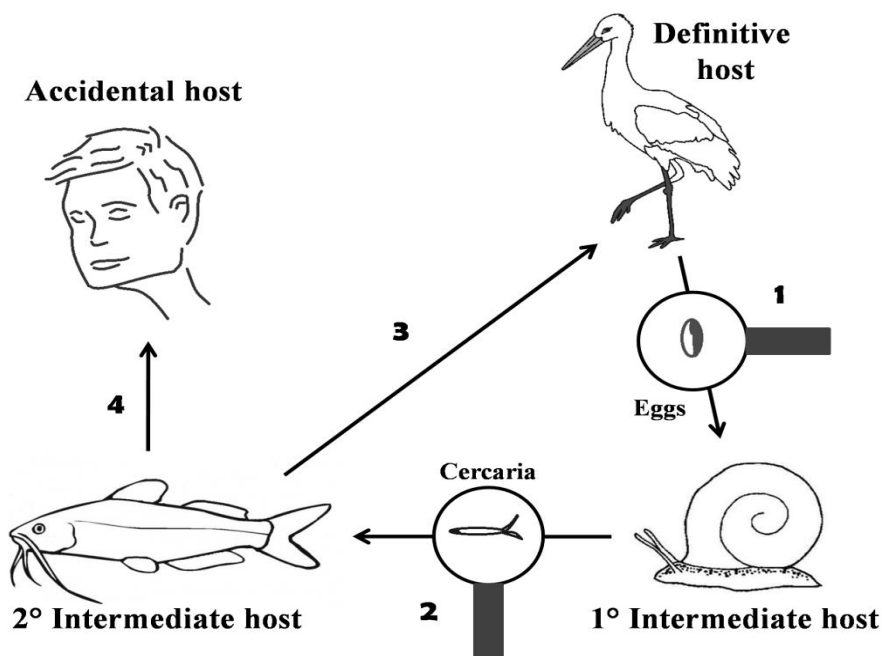
There are dozens of helminth parasites of fish that cause diseases in humans. Some examples are the nematodes of the family Anisakidae and *Eustrongylus* sp., the cestode *Diphyllobothrium* spp. and the trematode *Ascocotyle (Phagicola) longa* (OKUMURA et al., 1999). Several trematodes which parasitize fish and may cause human infection are allocated in the suborder Digenea. Such infections may be rare and occasional, as is the case of clinostomiasis, which is caused by *Clinostomum complanatum* (EIRAS, 1994). Besides its zoonotic potential, this trematode also deserves great attention for the losses in production and discards of fish carcasses.

### **Life Cycle**

*Clinostomum complanatum* is a digenetic endoparasite of vertebrates which belongs to the Clinostomidae family. It has been described as a parasite of fish-eating birds (Kagei et al., 1988; Dias et al., 2003b; Pesenti et al., 2007; Papazahariadou et al., 2008) and fresh and brackish water fish (Dias et al., 2003b; Aguilar-Aguilar et al., 2010; Gholami et al., 2011; Violante-Gonzalez et al., 2009) in many countries. Amphibians such as salamanders and frogs have been reported as hosts of *C. complanatum* and other clinostomes (MCALLISTER et al., 2007, 2010; LEMKE et al., 2008). Members of this family have already been registered in areas with an average temperature of 10°C, demonstrating its widespread distribution (GRABDA-KAZUBSKA, 1974). Most digenetic trematodes have a complex life cycle. Molluscs are almost always the obligatory intermediate hosts, and at least two hosts are involved, the definitive one being a fish or a piscivorous bird in most of the cases (Figure 1). Fish present the

unique potential of acting both as intermediate (harboring metacercariae) or definitive host (PAVANELLI et al., 2002). While studying the life cycle of *C. Complanatum* on the floodplain of high Paraná river (Brazil), DIAS et al. (2003b)

observed the mollusc species *Biomphalaria peregrina* as the first intermediate host, several fish species as the second, and various aquatic avian species as definitive hosts.



**Figure 1.** Biological cycle of *Clinostomum complanatum*. (1) An adult parasitizing a bird releases its eggs along with the host's feces. A mollusc feeds on the feces and ingests the eggs. (2) Free cercariae leave the mollusc and infect a fish (second host), in which cysts are developed (metacercariae). (3) A bird feeds on the fish and the parasite is freed in its digestive tract, thus completing the cycle. (4) A man eats raw or undercooked fish meat and becomes an accidental host.

The highest prevalence among the fishes was found in *Loricariichthys platymetopon* (60.8%), and among the birds in *Ardea cocoi* (95%). Fish species belonging to families such as Gymnotidae, Cichlidae (SILVA-SOUZA & LUDWIG, 2005), Characidae (ABDALLAH et al., 2004), Callichthyidae (DIAS et al., 2003b; ABDALLAH et al., 2006), Loricariidae (DIAS et al., 2003a) and Heptapteridae (VIANNA et al., 2005; MORAIS, 1980) have been found hosting *C. complanatum* in Brazilian rivers.

### **Patogenicity**

The adult form of *C. complanatum* is usually seen attached to the esophageal mucosa (DIAS et al., 2003a), oral cavity and lung (PESENTI et al., 2007) of piscivorous birds. DIAS et al. (2003a) observed an intense liquefactive necrosis in the attachment sites of *C. complanatum* in the oesophagus of *A. cocoi*. SHAMSI et al. (2013) reported that this digenea may inflict great pathological effect on the oral and oesophageal epithelium, as acute

inflammation in mucosal and submucosal layers and occasionally in muscular layer. The bird reacts to the infection through encapsulation of the larvae in fibrous tissue.

The histopathological evaluation of a bird (*Nycticorax nycticorax*) presenting heavy *C. complanatum* infestation showed severe necrosis and acute inflammation of the oral epithelial tissue and submucosa, with mononuclear cells being the dominant inflammatory cells around the attachment site. Sections of immature *C. complanatum* were also present in the muscular layer, in which the parasites were surrounded by a thin zone of necrotic cells and a capsule of fibrous tissue (SHAMSI et al., 2013). The authors suggested that the damaged tissues may interfere with the bird's ability to swallow and lead to malnutrition. As a result, the immune system is weakened and the animal is thus prone to more serious pathogens.

In fish *C. complanatum* larvae are found encysted in various regions of the

body, such as muscle, oral cavity, eyes, gills, subcutaneous tissue, gonads, intestines, liver and other organs (PAVANELLI et al., 2002; VIANNA et al., 2005; SILVA et al., 2008). According to MALEK & MOBEDI (2001), an inflammatory reaction usually occurs in the tissue surrounding the metacercariae, thus facilitating visualization of the parasite and preventing its ingestion. Nonetheless, the authors mentioned that some fish may become resistant to the presence of the metacercariae, in which case the inflammatory reaction is not triggered. That would make observation of the parasite difficult, especially when the cysts are embedded in the muscle, and accidental human infection would most likely occur.

### **Fish Culture**

The presence of encysted metacercariae of *C. complanatum* in fish characterizes the yellow spot disease (Figure 2). The unpleasant appearance of the fish is unappealing to the consumer, (SILVA-SOUZA & LUDWIG, 2005)

resulting in discard of carcasses during inspection and economic losses (BRANDÃO, 2004). In addition, the infection affects the fish's feeding habit, acquisition of body weight and fecundity, and may culminate in death.

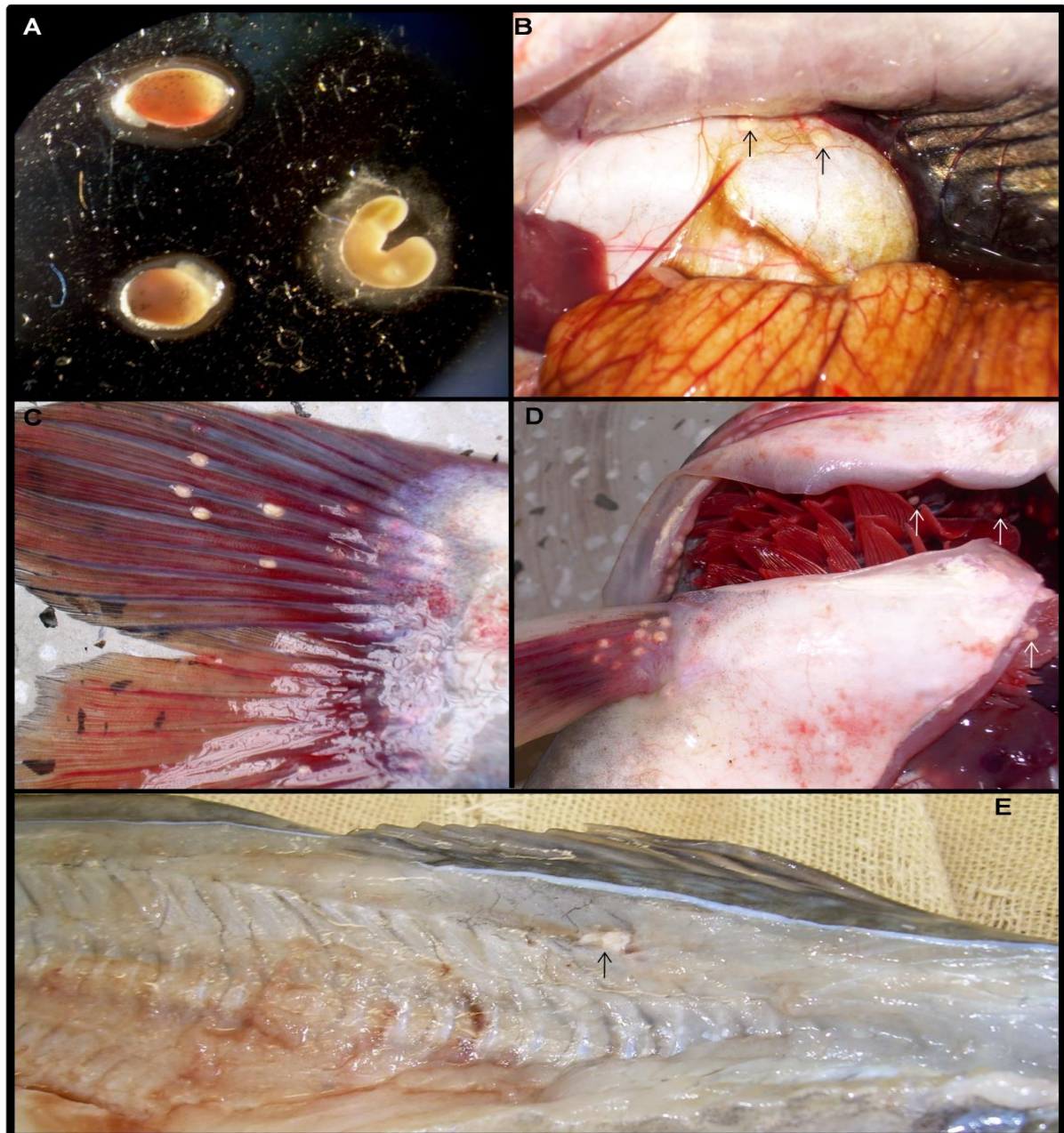Drugs containing praziquantel represent an alternative for the treatment of the yellow spot disease. However, the toxin released by the parasite upon death and the secondary infections that may install in the damaged tissue are likely to cause fish death (MITCHELL, 1995; SILVA et al., 2009).

Control of the parasite infestation in fish cultures is performed by interrupting its life cycle, so the presence of molluscs and aquatic avian species in the tanks ought to be avoided.

The prophylactic actions include annual tank disinfection with quicklime, a procedure which prevents mollusc perpetuation and therefore ends the biological cycle of the trematode (BRANDÃO, 2004).

In Rio Grande do Sul, south Brazil, *C. complanatum* has been reported occurring in free-living fishes as well as in cultured species, namely *Rhamdia quelen*,

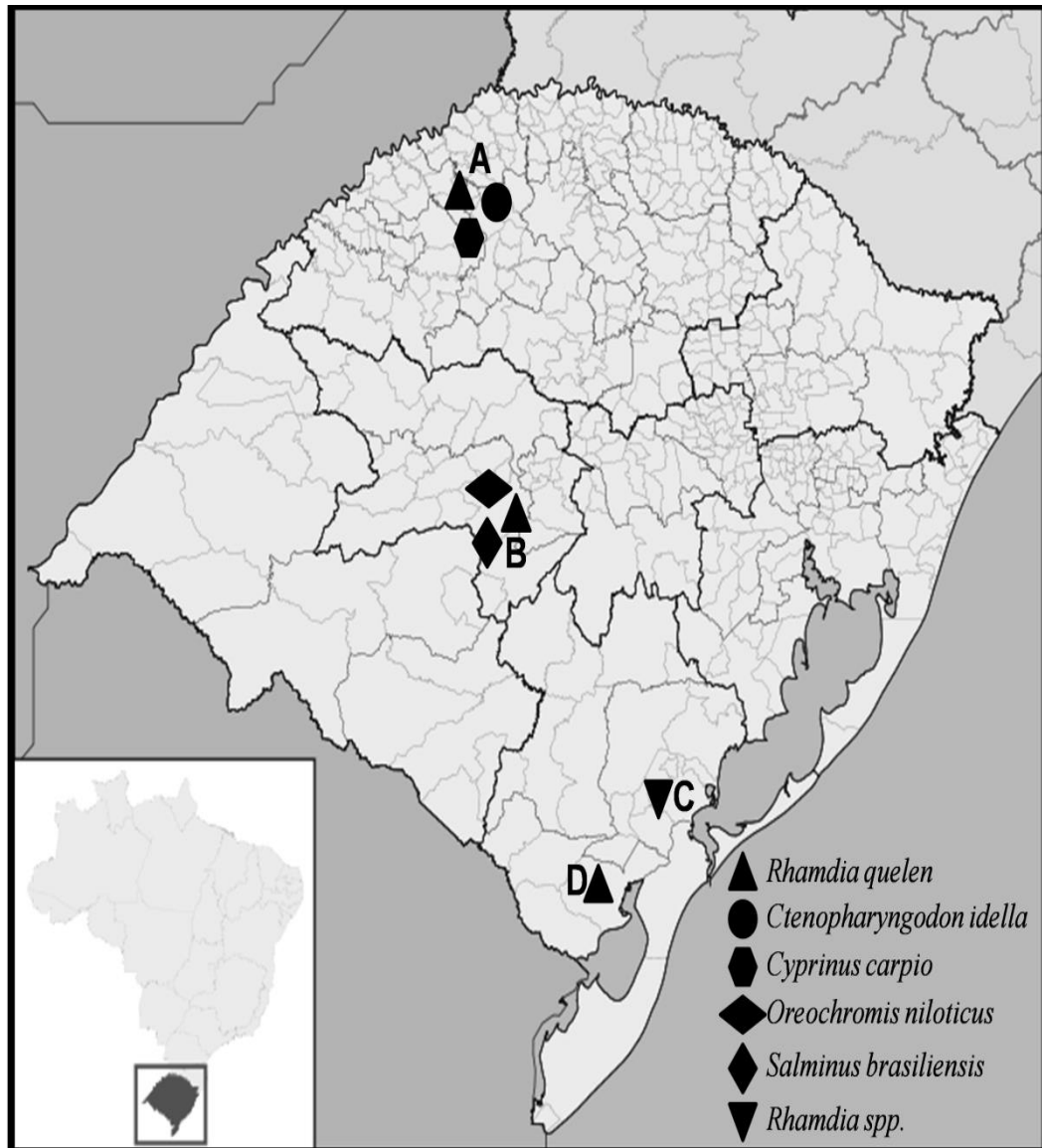
*Oreochromis niloticus*, *Salminus brasiliensis*, *Ctenopharyngodon idella* and *Cyprinus carpio*.



**Figure 2.** Metacercarial cysts of *Clinostomum complanatum* isolated from *Rhamdia quelen* (A), encysted in swim bladder (B), caudal fin (C), pectoral fin, operculum, muscle and gills (D), and ruptured cyst in muscle (E).

The registers were made in Santa Maria (SILVA et al., 2008), Arroio Grande (MORAIS, 1980) and Alegria (LIMA et al., 2014). In Pelotas, DIAS et al. (2006)

observed the presence of *Clinostomum* spp. in *Rhamdia* spp. commercialized in local fish shops (Figure 3).



**Figure 3.** Occurrence of *Clinostomum complanatum* in fish originated from fish farms and shops in cities of Rio Grande do Sul (south Brazil): Alegria (A), Santa Maria (B), Pelotas (C) and Arroio Grande (D).



Considering the presence of this endoparasite in fish traded in fish cultures and shops, PAVANELLI et al. (2002) suggested that public organs should adopt preventive measures as a means of minimizing or even preventing the transmission of parasitic diseases in fish farming. Inspections performed by specialists with the aim of proving the absence of pathogens in fish cultures and dispatched as a sanitary certificate represent an alternative to attest that fish to be transported do not pose any threat of disease transmission to other fish farms.

### **Human Cases**

The World Health Organization has acknowledged the serious health concern that fish-borne trematodes represent to humans (WHO, 1995).

In the case of *C. complanatum*, after consumption of raw or undercooked parasitized fish, the metacercariae are freed in the stomach and the parasite migrates towards the esophagus or the oral cavity,

usually causing acute pharyngitis or laryngitis (PARK et al., 2009).

The first case of clinostomiasis was registered in Japan (YAMASHITA, 1938), and most of the reports of human parasitism by *Clinostomum* sp. were also registered in that country. SHIRAI et al. (1998) documented the case of a 29-year-old Japanese woman with throat discomfort and worm expectoration through sneezes. In Thailand a 38-year-old man visited an ophthalmology clinic with complaints of itches in the right eye, and examination revealed the presence of a worm attached to the lacrimal orifice. The parasite was removed and identified as *Clinostomum* sp. The patient had recently eaten raw fresh water fish (TIEWCHALOREN et al., 1999). CHUNG et al. (1995) reported the first Korean case of pharyngitis caused by *C. complanatum*. A few days after eating raw fish, a 56-year-old man visited an otorhinolaryngology clinic describing a foreign body sensation

and pain in the pharynx. Exams showed a live worm adhered to the mucous membrane. The second case in that country occurred in a 33-year-old man who also had the history of eating raw fish (PARK et al., 2009). Endoscopy demonstrated the presence of a 5 mm worm attached to the arytenoid region. Petechial hemorrhage was evident on the mucosa after removal of the worm, which presented dark-brown granules in its interior suggesting it could feed on blood sucked from the mucosa.

There is no therapeutic drug for the treatment of clinostomiasis in humans, should mechanical extraction be promptly performed under general anesthesia. Since the procedure may be hampered by the firm adherence of the parasite to the mucosa and by its fast movement, application of lidocaine onto the worm is recommended in order to paralyze it and eliminate its suction (KITAGAWA et al., 2003).

## **Conclusion**

There is an increase demand for fish production in Brazil, since human consumption of fish meat is steadily growing.

However, the occurrence of infestation by parasites such as *C. complanatum* is likely to increase due to fish culture intensification. In this way, strict and effective regulations ought to be implemented by sanitary inspectors, producers, veterinarians and all of the professionals involved in the fish production chain with the aim of reducing the economic losses as well as the risks of disease transmission to humans.

Furthermore, the offer of raw fish dishes in restaurants should equally occur under rigorous sanitary control, and the population should be alerted about the potential dangers of eating raw fish meat.

## References

- ABDALLAH, V.D.; AZEVEDO, R.K.; LUQUE, J.L. Ecologia da comunidade de metazoários parasitos do tamboatá *Hoplosternum littorale* (Hancock, 1828) (Siluriformes: Callichthyidae) do Rio Guandu, Estado do Rio de Janeiro, Brasil. **Acta Scientiarum Biological Sciences**, v.28, n.4, p.413-419, 2006.
- ABDALLAH, V.D.; AZEVEDO, R.K.; LUQUE, J.L. Metazoários parasitos dos lambaris *Astyanax bimaculatus* (Linnaeus, 1758), *A. parahybae* Eigenman, 1908 e *Oligosarcus hepsetus* (Cuvier, 1829) (Osteichthyes: Characidae), do Rio Guandu, Estado do Rio de Janeiro, Brasil. **Revista Brasileira de Parasitologia Veterinária**, v.13, n.2, p.57-63, 2004.
- AGUILAR-AGUILAR, R.; ROSAS-VALDEZ, R.; MARTÍNEZ-AQUINO, A.; PÉREZ-RODRÍGUEZ, R.; DOMÍNGUEZ-DOMÍNGUEZ, O.; PÉREZ-PONCE DE LEÓN, G. Helminth fauna of two cyprinid fish (*Campostoma ornatum* and *Codoma ornata*) from the upper Piaxtla River, Northwestern Mexico. **Helminthologia**, v.47, n.4, p.251-256, 2010.
- BARROS, L.A.; MORAES FILHO, J.; DE OLIVEIRA, R.L. Nematóides com potencial zoonótico em peixes com importância econômica provenientes do Rio Cuiabá. **Revista Brasileira de Ciências Veterinárias**, v.13, n.1, p.55-57, 2006.
- BRANDÃO, D.A. Profilaxia e Doenças. In: BALDISSEROTTO, B., RADÜNZ NETO, J. Criação de jundiá. Ed. UFSM, Santa Maria, 2004. 232p.
- CHUNG D.I.; MOON, C.H.; KONG, H.H.; CHOI, D.W.; LIM, D.K. The first human case of *Clinostomum complanatum* (Trematoda: Clinostomidae) infection in Korea. **Korean Journal Parasitology**, v.33, n.3, p.219-23, 1995.

DIAS, J.S.; RODRIGUES, A.P.; NEILA, C.M.; BERNE, M.E.A. *Clinostomum* spp. (trematoda: digenea) em *Rhamdia* spp. (jundiá) comercializados em Pelotas, RS. In. XV Congresso de Iniciação Científica e VIII Encontro de Pós-graduação da UFPel, Pelotas, 2006.

DIAS, M.L.G.G.; EIRAS, J.C.; MACHADO, M.H.; SOUZA, G.T.; PAVANELLI, G.C. The attachment of *Clinostomum* sp. (Digenea, Clinostomidae) to the oesophagus of the bird *Ardea cocoi* (Aves, Ardeidae). **Parasite**, v.10, n.2, p.185-187, 2003a.

DIAS, M.L.G.G.; EIRAS, J.C.; MACHADO, M.H.; SOUZA, G.T.; PAVANELLI, G.C. The life cycle of *Clinostomum complanatum* Rudolphi, 1814 (Digenea, Clinostomidae) on the floodplain of the high Paraná River, Brazil. **Parasitology Research**, v.89, p.506-508, 2003b.

EIRAS, J. C. A importância econômica dos parasitas de peixes. **Higiene Alimentar**, v.8, n.31, p.11-13, 1994.

GHOLAMI, Z.; MOBEDI, I.; ESMAEILI H.R.; KIA; E.B. Occurrence of *Clinostomum complanatum* in *Aphanius dispar* (Actinopterygii: Cyprinodontidae) collected from Mehran river, Hormuzgan Province, South of Iran. **Asian Pacific Journal of Tropical Biomedicine**, v.1, n. 3, p.189-192, 2011.

GRABDA-KAZUBSKA, B. *Clinostomum complanatum* (Rudolphi, 1819) and *Euclinostomum heterostomum* (Rudolphi, 1819) (Trematoda, Clinostomatidae), their occurrence and possibility of acclimatization in artificially heated lakes in Poland. **Acta Parasitologica**, v.22, p.285-293, 1974.

KAGEI, N.; YANOHARA, Y.; UCHIKAWA, R.; SATO, A. Natural infection with *Clinostomum complanatum* (Rudolphi. 1819) in the birds of southern Japan. **Japanese Journal of Parasitology**, v.37, n.4, p.254-7, 1988.

KITAGAWA, N.; ODA, M.; TOTOKI, T.; WASHIZAKI, S.; ODA, M.; KIFUNE, T. Lidocaine spray used to capture a live

*Clinostomum* parasite causing human laryngitis. **American Journal of Otolaryngology**, v.24, p.341-343, 2003.

LEMKE, L.B.; DRONEN, N.; FOX, J.G.; NAMBIAR, P.R. Infestation of wild-caught American bullfrogs (*Rana catesbeiana*) by multiple species of metazoan parasites. **Journal of the American Association for Laboratory Animal Science**, v.47, n.3, p.42-46, 2008.

LIMA, H.; STEFANI, L.; PEDRON, F.; BALDISSERA, M.; DA SILVA A. Proinflammatory cytokines in the serum of silver catfish (*Rhamdia quelen*) naturally infected by *Clinostomum complanatum*: A preliminary study. **Journal of Parasitology** (in press), 2013.

MALEK, M., MOBEDI, I. Occurrence of *Clinostomum Complanatum* (Rudolphi, 1819) (Digenea: Clinostomatidae) in *Capoeta capoeta gracilis* (Osteichthys: Cyprinidae) from Shiroud River, Iran. **Iranian Journal Public Health**, v.30, p.95-98, 2001.

MCALLISTER, C.T.; BURSEY, C.R.; CRAWFORD, J.A.; KUHNS, A.R.; SHAFFER, C.; TRAUTH, S.E. Metacercariae of *Clinostomum* (Trematoda: Digenea) from three species of *Ambystoma* (Caudata: Ambystomatidae) from Arkansas and Illinois, U.S.A. **Comparative Parasitology**, v.77, n.1, p.25-30, 2010.

MCALLISTER, C.T.; BURSEY, C.R.; NIEMILLER, M.L.; MILLER, B.T. A noteworthy infection of *Clinostomum complanatum* (Digenea: Clinostomidae) in a cave salamander, *Eurycea lucifuga* (Caudata: Plethodontidae), from northcentral Tennessee. **Texas Journal of Science**, v.59, p.321–326, 2007.

MITCHELL, A.J. Importance of treatment duration for praziquantel used against larval digenetic trematodes in sunshine Bass. **Journal of Aquatic Animals Health**, v.7, n.4, p.327-330, 1995.

MORAIS, N.C.M. **Helintos parasitos de jundiá, *Rhamdia quelen* (Quoy & Gaimard, 1824) (Siluriformes) coletados em ambiente natural e em estação de piscicultura, no sul do RS.** Pelotas. 70p. Dissertação (Mestrado em Medicina Veterinária) – Universidade Federal de Pelotas, 1980.

OKUMURA, M.P.M.; PEREZ A.C.A.; ESPINDOLA FILHO, A. Principais zoonoses parasitárias transmitidas por pescado – revisão. **Revista de Educação Continuada do CRMV-SP**, v.2, n.2, p.66-80, 1999.

PAPAZAHARIADOU, M.; DIAKOU, A.; PAPADOPOULOS, E.; GEORGOPOULOU, I.; KOMNENOU, A.; ANTONIADOU-SOTIRIADOU, K. Parasites of the digestive tract in free-ranging birds in Greece. **Journal of Natural History**, v.42, p.381-398, 2008.

PARK, C.W., KIM, J.S.; JOO, H.S.; KIM, J. A human case of *Clinostomum complanatum* infection in Korea. **Korean**

**Journal Parasitology**, v.47, n.4, p.401-4, 2009.

PAVANELLI, G.C.; EIRAS, J.C.; TAKEMOTO, R.M. Doenças de peixes: profilaxia, diagnóstico e tratamento. 2ª ed., Maringá, Ed. UEM, 2002. 305p.

PESENTI, T.C.; SILVA, D.S.; KRUGER, C.; MASCARENHAS, C.S.; MULLER, G. Trematódeos parasitos de *Nycticorax nycticorax* (Savacu) (Aves: Ardeidae) no Rio Grande do Sul. In: XVI Congresso de Iniciação Científica e IX Encontro de Pós-graduação da UFPel, Pelotas, 2007.

SHAMSI, S.; HALAJIANB, A.; TAVAKOLB, S.; MORTAZAVID, P.; BOULTONA, J. Pathogenicity of *Clinostomum complanatum* (Digenea: Clinostomidae) in piscivorous birds. v.95, p.537–539, 2013.

SHIRAI, R.; MATSUBARA, K.; OHNISHI, T.; NISHIYAMA, H.; MIYAMOTO, J.; WATANABE, A.; HARADA, R.; KADOTA, J.; KOHNO, S. A case of human infection with

*Clinostomum* sp. **Kansenshogaku Zasshi**, v.72, p.1242-1245, 1998.

SILVA, A.S. PEDRON, F.A.; ZANETTE, R.A.; MONTEIRO, S.G., RADÜNZ NETO, R. Eficácia do praziquantel no controle ao parasito *Clinostomum complanatum* Rudolphi, 1918 (Digenea, Clinostomidae) em peixes da espécie *Rhamdia quelen* Quoy & Gaimard, 1824 (jundiá). **Pesquisa Agropecuária Gaúcha**, v.15, n.1, 73-76, 2009.

SILVA, A.S.; MONTERIO, S.G.; DOYLE, R.L.; PEDRON, F.A.; FILIPETTO, J.E.S.; NETO, J.R. Ocorrência de *Clinostomum complanatum* em diferentes espécies de peixes de uma piscicultura do município de Santa Maria - RS. **Veterinária e Zootecnia**, v.15, n.1, p.27-32, 2008.

SILVA-SOUZA, A.T.; LUDWIG, G. Parasitism of *Cichlasoma paranaense* (Kullander, 1983) and *Gymnotus carapo* (Linnaeus, 1814) by *Clinostomum complanatum* (Rudolphi, 1814) metacercariae in the Taquari River.

**Brazilian Journal of Biology**, v.65, n.3, p.513-519, 2005.

TIEWCHALOERN, S.; UDOMKIJDECHA, S.; SUVOUTTHO, S.; CHNCHAMSRI, K.; WAIKAGUL, J. *Clinostomum* trematode from human eye. **Southeast Asian Journal of Tropical Medicine and Public Health**, v.30, n.2, p.382-4, 1999.

VIANNA, R.T.; PEREIRA, J.J.; BRANDÃO, D.A. *Clinostomum complanatum* (Digenea, Clinostomidae) density in *Rhamdia quelen* (Siluriformes, Pimelodidae) from South Brazil. **Brazilian Archives of Biology and Technology**, v.48, n.4, p.635-642, 2005.

VIOLANTE-GONZÁLEZ, J.; AGUIRRE-MACEDO, M.L.; ROJAS-HERRERA, A.; GUERRERO, S.G. Metazoan parasite community of blue sea catfish, *Sciades guatemalensis* (Ariidae), from Tres Palos Lagoon, Guerrero, Mexico. **Parasitology Research**, v.105, p.997–1005, 2009.

WORLD HEALTH ORGANIZATION.

Control of foodborne trematodes infections. Geneva: WHO; 1995, p. 1-107.

YAMASHITA, J. *Clinostomum complanatum*, a trematode parasite new to

man. **Annotationes Zoologicae**

**Japonenses**, v.17, p.563-566, 1938.