

Unilateral retinitis pigmentosa: case report

Retinose pigmentar unilateral: relato de caso

Ricardo Evangelista Marrocos de Aragão¹. Ieda Maria Alexandre Barreira². Ariane Sa Vieira Bastos³. Gustavo Jose Arruda Mendes Carneiro⁴. Talles Peterson Cavalcante Oria⁴.

1 Doutor em Medicina pela Universidade de Regensburg, Alemanha; Preceptor de Retina do Hospital Universitário Walter Cantídio, Universidade Federal do Ceará (UFC), Fortaleza, Ceará, Brasil. 2 Especialista em retina pela Universidade Federal de São Paulo (UNIFESP). 3 Fellow em Plástica Ocular do Serviço de Oftalmologia do Hospital Universitário Walter Cantídio, Universidade Federal do Ceará UFC, Fortaleza, Ceará, Brasil. 4 Residente do segundo ano do Serviço de Oftalmologia do Hospital Universitário Walter Cantídio, Universidade Federal do Ceará UFC, Fortaleza, Ceará, Brasil.

ABSTRACT

Unilateral retinitis pigmentosa (URP) is a rare tapetoretinal dystrophy affecting only one eye. Criteria are necessary to make a correct diagnosis of URP: exclude all infective etiologies, check that the clinical signs of retinitis are present in the affected eye and the total absence of any signs or symptoms of retinitis pigmentosa in the fellow eye. Electroretinogram (ERG) and electro-oculogram (EOG) are useful for the correct diagnosis. In this paper we report one case.

Keywords: Retina. Photoreceptor cells, vertebrate. Retinitis pigmentosa. Vision, ocular. Mutation.

RESUMO

Retinose pigmentar unilateral é uma distrofia tapetoretiniana rara afetando somente um olho. Critérios devem ser empregados para um diagnóstico correto: exclusão de todas etiologias infecciosas que cursam com quadro semelhante, presença dos sinais clínicos de retinose pigmentar no olho afetado e ausência de qualquer sinal no olho contralateral. Eletroretinograma (ERG) e eletro-oculograma (EOG) são bastante úteis no diagnóstico. Neste artigo relatamos o caso de uma paciente.

Palavras-chave: Retina. Células fotoreceptoras de vertebrados. Retinite pigmentosa. Visão ocular. Mutação.

Corresponding Author: Ricardo Evangelista Marrocos de Aragão. Rua Osvaldo Cruz, 2335, Bairro Dionísio Torres, Fortaleza, Ceará. CEP:60125-151. Telefone: +55 85 32617528. E-mail: ricardomarrocos@yahoo.com

Conflict of interests: The authors have no conflicts of interest to declare.

Received: 20 Jul 2015; Revised: 12 Aug 2015; Accepted: 25 Sep 2015.

INTRODUCTION

Retinitis Pigmentosa (RP) is a group of inherited disorders of the retina which are characterized by progressive damage involving photoreceptors and often, subsequently other cell layers, associated with progressive cell loss and eventual atrophy of several retina layers. The consequent visual impairment is usually manifested as night blindness, visual field loss and, in some cases, central visual disorders.¹ RP is a hereditary disorder that can be autosomal dominant, autosomal recessive or X-linked.² The classically described fundus appearance of RP includes attenuated retinal vessels, mottling and granularity of the retinal pigment epithelium (RPE), bone-spicule intraretinal pigmentation and optic nerve head pallor.³ Presentation is bilateral and symmetrical. Unilateral retinitis pigmentosa (URP) is a rare condition. The vast majority of the published cases, were reported before the advent of electroretinography (ERG) and electrooculography (EOG). The diagnosis was based on symptoms and fundus features only, and in that way may have resulted from other acquired diseases. Ocular eye trauma, syphilis or other ocular inflammation can mimic URP.

Despite patients with URP have been described, none of these cases have been reported to be familial or associated with gene mutation and the cause of these cases remains unclear.⁴ A close relationship between URP and bilateral retinitis pigmentosa

has been described, but the genetic mechanisms to explain this remain to be identified.

CASE REPORT

A 60 year-old female was referred to us with headache complains. She had controlled hypertension. Her family history was normal.

On examination, best-corrected visual acuity (BCVA) was 20/80 in the right eye (RE) and 20/40 in the left eye (LE). The slitlamp examination had shown in OU subcapsular cataract, more in the RE. Intraocular pressure was normal in both eyes. The fundus appearance was characterized by typical bone spicule formation in the midperipheral retina, associated with waxy color of the optic disk, narrowed retinal vessels and tobacco dust in the vitreous in the RE. The LE was normal (Figures 1 and 2). Computadorized visual field examination in the RE was tubular, with subnormal foveal value, while in the LE it was normal (Figure 3). The flash ERG, performed according to the ISCEV (International Society for Clinical Electrophysiology of Vision) standards, was markedly low in both photopic and scotopic components, while in the left eye it was normal (Figure 4). The standard EOG was subnormal in the RE and normal in the LE. (Figure 5).

Figure 1. Fluorescein angiography of the right eye.

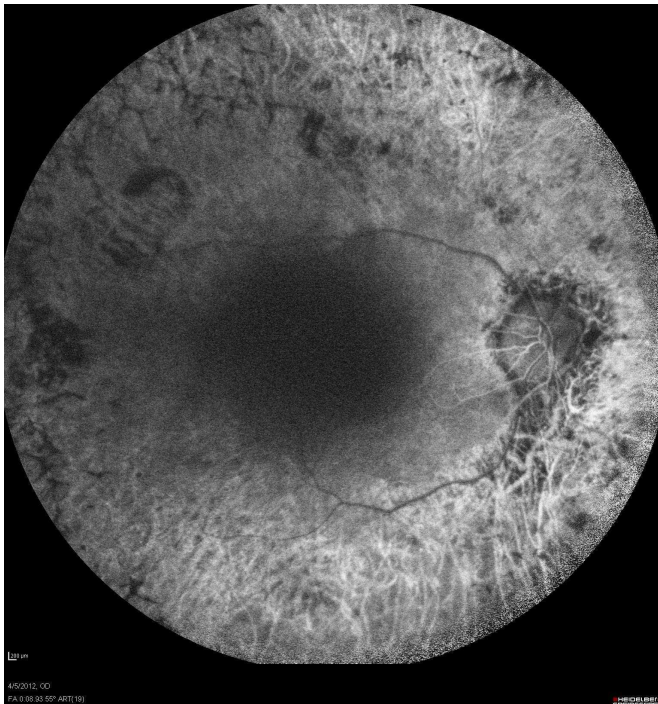


Figure 2. Fluorescein angiography of the left eye.

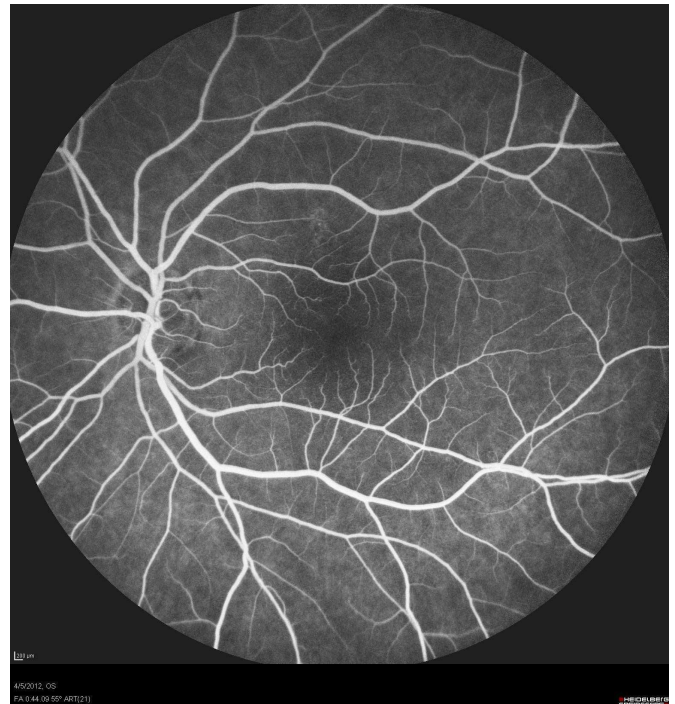

Figure 3. Computadorized visual Field RE and LE.

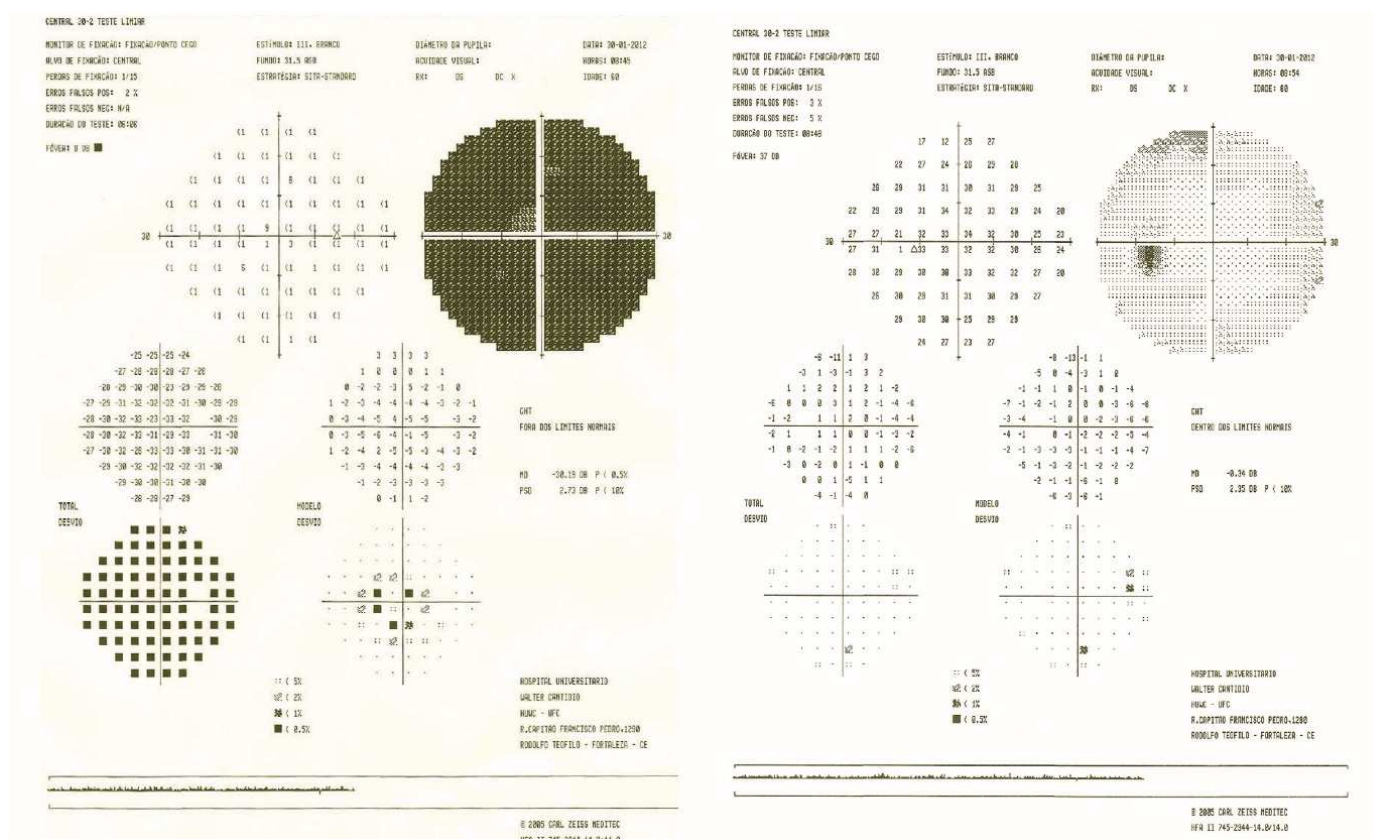


Figure 4. ERG RE and LE.

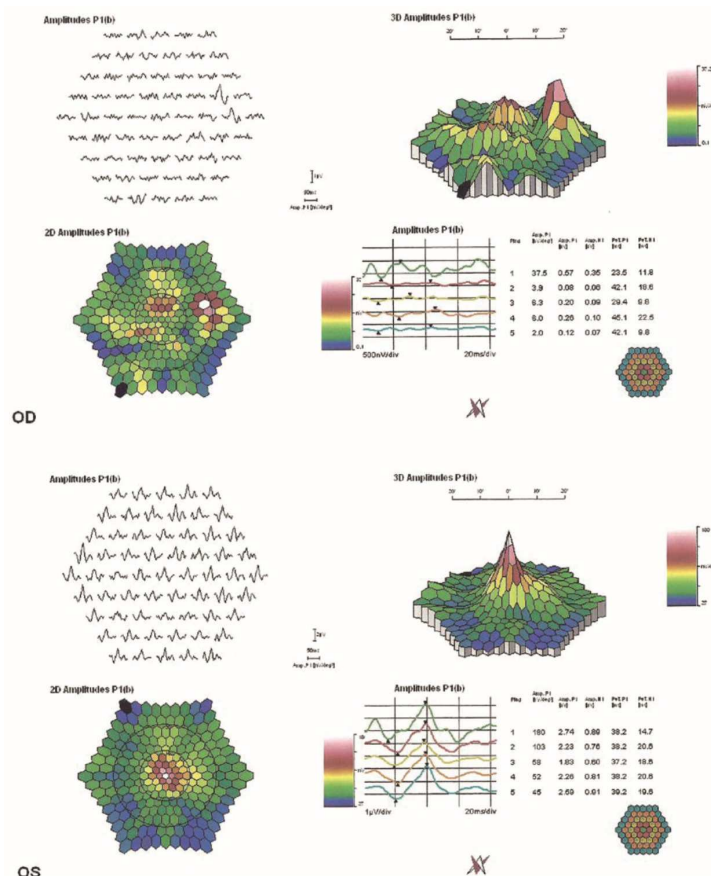
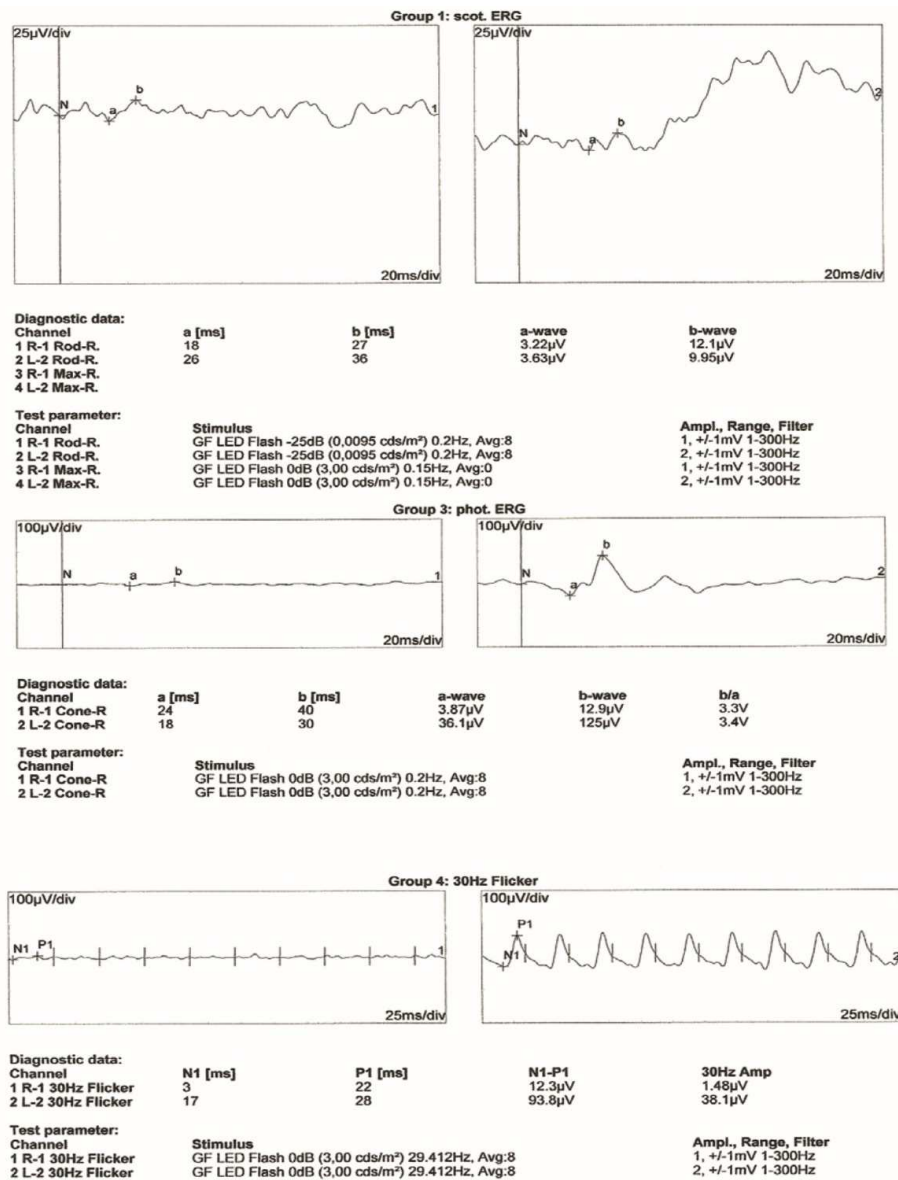


Figure 5. EOG RE and LE.



DISCUSSION

URP is a rare degeneration of photoreceptors involving retinitis pigmentosa-like changes in one eye with the other eye completely unaffected. The criteria for diagnosis of URP are: 1. The presence in the affected eye of functional changes and an ophthalmoscopic appearance typical of retinitis pigmentosa. 2. The absence in the other eye of symptoms of a RP with the presence of a normal electroretinogram (ERG). 3. A sufficiently long period of observation. (over 5 years) to rule out a delayed onset in the unaffected eye. 4. Exclusion of an inflammatory or trauma cause in the affected eye.² RP frequently has a hereditary predisposition. URP instead, appears more frequently in adult age, and sporadically.¹ Many other inherited retinal conditions may be confused with RP. These can be conditions confined to the retina or have associated systemic manifestations that may or may not be apparent at the time of examination. A number of acquired conditions can cause extensive chorioretinal atrophy that is

difficult to distinguish from advanced RP. In such situations, specific details of the history or asymmetry of disease may be the most important differentiating factors. Differential diagnosis of pseudoretinitis pigmentosas include retinal inflammatory diseases like, rubella retinopathy, syphilis, infections retinitis, autoimmune paraneoplastic retinopathy: drug toxicity. Traumatic retinopathy is probably the commonest acquired⁵⁻⁸ retinopathy that is confused with RP and may, with diffused unilateral subacute neuroretinitis (DUSN), account for many previously misnamed case of URP.²

URP without pigmentary changes has been reported as well. It has been associated with heterochromia iridis, temporal arteritis, pit of optic disc, exfoliation syndrome, and glaucoma. Whether it is related with URP or they were just incidental findings is not clear, since only one case of each has been reported.

Unilateral retinitis pigmentosa is a very rare ocular disease,

thus to confirm the diagnosis of URP in our patient, a follow-up of at least 5 years must be performed to exclude a delay onset in the affected eye.

REFERENCES

1. Spadea L, Magni R, Ribaldi G, Dragani T, Bianco G. Unilateral retinitis pigmentosa: clinical and electrophysiological report of four cases. *Ophthalmologica*. 1998;212(5):350-4.
2. Thakur A, Puri L. Unilateral retinitis pigmentosa. *Clin Exp Optom*. 2010;93(2):102-4.
3. Ryan SJ, Hinton DR, Schachat AP, Wilkinson CP. *Retina*. 5th ed. Philadelphia: Elsevier Mosby; 2006.
4. Mukhopadhyay R, Holder GE, Moore AT, Webster AR. Unilateral retinitis pigmentosa occurring in an individual with a germline mutation in the RP1 gene. *Arch Ophthalmol*. 2011;129(7):954-6.
5. Traversi C, Tosi GM, Caporossi A. Unilateral retinitis pigmentosa in a woman and pigmented paravenous chorioretinal atrophy in her daughter and son. *Eye (London)*. 2000;14(Pt 3A):395-7.
6. Farrell DF. Unilateral retinitis pigmentosa and cone-rod dystrophy. *Clin Ophthalmol*. 2009;3:263-70.
7. Cestari, AT, Sallum JM, De Conti ML, Tagliari TI, Barboza MN. Retinose pigmentada unilateral secundaria a trauma: relato de caso. *Arq Bras Oftalmol*. 2012;75(3):210-2.
8. Rios DF, Carneiro LF, Cunha AA, Dalle CB, Frasson M. Retinose pigmentar unilateral ou pseudoretinose pigmentar?: relato de caso. *Arq Bras Oftalmol*. 2013;76(6):383-5.

Como citar:

Aragão RE, Barreira IM, Bastos AS, Carneiro GJ, Oria TP. Unilateral retinitis pigmentosa: case report. *Rev Med UFC*. 2015 jul-dez;55(2):54-58.